



Emerging strategies for the diagnosis and treatment of meibomian gland dysfunction: Proceedings of the OCEAN group meeting



Gerd Geerling^{a,*,1}, Christophe Baudouin^{b,**,1}, Pasquale Aragona^c, Maurizio Rolando^d, Kostas G. Boboridis^e, José M. Benítez-del-Castillo^f, Yonca A. Akova^g, Jesús Merayo-Llodes^h, Marc Labetoulleⁱ, Martin Steinhoff^j, Elisabeth M. Messmer^k

^a Department of Ophthalmology, University Hospital Duesseldorf, Heinrich-Heine University, Duesseldorf, Germany

^b Centre Hospitalier National d'Ophthalmologie des Quinze-Vingts, University Paris-Saclay, Paris, France

^c Institute of Ophthalmology, Department of Biomedical Sciences, University of Messina, Messina, Italy

^d Ocular Surface Centre, ISPRE Ophthalmics, Genoa, Italy

^e Department of Ophthalmology, Aristotle University of Thessaloniki, Thessaloniki, Greece

^f Hospital Clínico San Carlos, University Complutense, Madrid, Spain

^g Department of Ophthalmology, Bayındır Hospital, Ankara, Turkey

^h Instituto Universitario Fernández-Vega, University of Oviedo, Asturias, Spain

ⁱ Service d'Ophthalmologie, CHU Bicêtre, APHP, Université Paris-Sud, Le Kremlin-Bicêtre, Paris, France

^j Department of Dermatology and UCD Charles Institute for Translational Dermatology, University College Dublin, Dublin, Ireland

^k Department of Ophthalmology, Ludwig Maximilian University, Munich, Germany

ARTICLE INFO

Article history:

Received 10 February 2016

Received in revised form

20 January 2017

Accepted 23 January 2017

Keywords:

Dry eye disease

Meibomian gland dysfunction

ABSTRACT

Meibomian gland dysfunction (MGD) is a common and chronic disorder that has a significant adverse impact on patients' quality of life. It is a leading cause of evaporative dry eye disease (DED), as meibomian glands play an important role in providing lipids to the tear film, which helps to retard the evaporation of tears from the ocular surface. MGD is also often present in conjunction with primary aqueous-deficient DED. Obstructive MGD, the most commonly observed type of MGD, is the main focus of this article. MGD is probably caused by a combination of separate conditions: primary obstructive hyperkeratinization of the meibomian gland, abnormal meibomian gland secretion, eyelid inflammation, corneal inflammation and damage, microbiological changes, and DED. Furthermore, skin diseases such as rosacea may play a part in its pathology. Accurate diagnosis is challenging, as it is difficult to differentiate between ocular surface diseases, but is crucial when choosing treatment options. Ocular imaging has advanced in recent years, providing ophthalmologists with a better understanding of ocular diseases. This review presents a literature update on the 2011 MGD workshop and an optimized approach to accurate diagnosis of MGD using currently available methods and tests. It also outlines the emerging technologies of interferometry, non-contact meibography, keratography and *in vivo* confocal laser microscopy, which offer exciting possibilities for the future. Selected treatment options for MGD are also discussed.

© 2017 The Authors. Published by Elsevier Inc. This is an open access article under the CC BY-NC-ND license (<http://creativecommons.org/licenses/by-nc-nd/4.0/>).

1. Introduction

Meibomian gland dysfunction (MGD) is a leading cause of evaporative dry eye disease (DED) and is one of the most common diseases encountered in the ophthalmology clinic [1–3]. The impact of MGD on patients can be severe, with a negative effect on their quality of life that may lead to a loss of productivity [4,5]. Obstructive MGD is the most commonly observed type of MGD [6] and is the main focus of this article. Obstructive MGD is associated with changes such as hypertrophy of the duct epithelium and keratinization of the orifice epithelium [6]. Terminal duct

* Corresponding author. Department of Ophthalmology, University Hospital Duesseldorf, Heinrich-Heine University, Moorenstr. 5, Duesseldorf, NRW D-40225, Germany.

** Corresponding author. Centre Hospitalier National d'Ophthalmologie des Quinze-Vingts, University Paris-Saclay, 28 Rue de Charenton, 75 012, Paris, France.

E-mail addresses: geerling@med.uni-duesseldorf.de (G. Geerling), chrbaudouin@aol.com (C. Baudouin).

¹ These authors contributed equally to this manuscript.

obstruction or altered secretion causes low delivery of meibum to the ocular surface [6].

The 2011 International Workshop on MGD represented a significant advance in the understanding, classification, diagnosis and treatment of the disease [7]. The classification system developed by the International Workshop recognizes that although MGD may occur without DED, MGD may lead to evaporative DED when signs are sufficiently severe [7]. Nevertheless, some confusion persists around whether MGD is primary or secondary to DED, whether MGD is part of the vicious circle of events of DED, and which symptoms are related to MGD and which are related to DED [7–9]. The causative association between MGD and DED is strongly debated; MGD may lead to DED through a process of events that involves inflammation, but equally, the surface inflammation of the eyelid margin in DED may affect meibomian gland morphology and function, giving rise to MGD [8]. Some types of MGD are also associated with ocular rosacea and other skin sebaceous gland conditions [10].

General ophthalmologists face a challenge in differentiating MGD from other forms of DED and in identifying subforms such as dermatitis-associated MGD, to inform their management decisions. This review presents the results of discussions held by the OCEAN

group in 2014 and aims to provide a practical guide to understanding and diagnosing MGD for the general ophthalmologist. New and emerging techniques for diagnosing all forms of MGD are examined for their potential usefulness, and some guidance for selecting the most appropriate treatment is provided. In addition, the expanded version of the vicious circle of DED that encompasses MGD pathology is presented (Fig. 1) [11–13].

2. MGD: pathology and prevalence

Meibomian glands are found in the upper and lower eyelids, and their role is to secrete lipids (meibum) onto the ocular surface that forms the outermost layer of the tear film; these lipids spread easily, promoting stability and protecting against evaporation [6,14]. MGD-related DED is currently defined as ‘a chronic, diffuse abnormality of the meibomian glands, commonly characterized by terminal duct obstruction and/or qualitative/quantitative changes in the glandular secretion. It may result in alteration of the tear film, symptoms of eye irritation, clinically apparent inflammation and ocular surface disease.’ [7] It is beyond the scope of this paper to describe in detail the pathology of MGD; however, the OCEAN group recognizes that MGD is a heterogeneous condition and

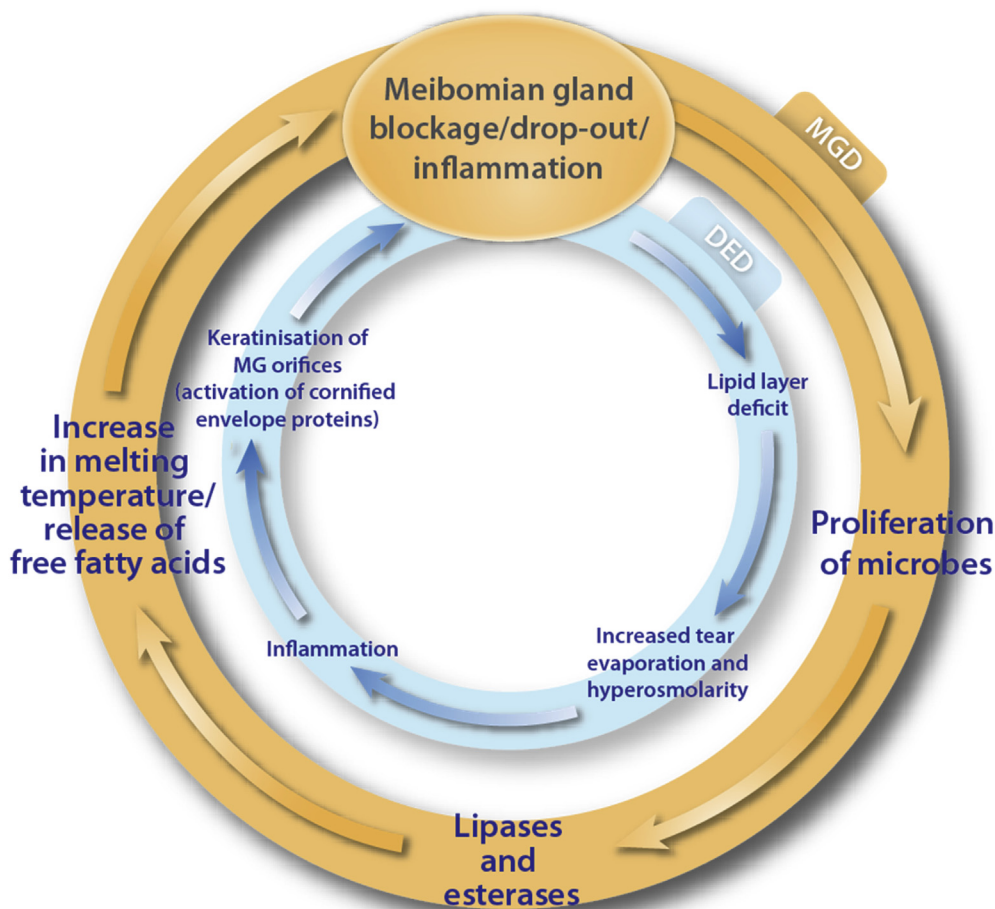


Fig. 1. Importance of MGD in the vicious circle of MGD-related DED pathology. DED, dry eye disease; MG, meibomian gland; MGD, meibomian gland dysfunction. Reproduced with permission from Baudouin et al. [13]. The first circle illustrates the proposal that MGD, diagnosed by blockage/atrophy of meibomian glands, could lead to a proliferation of microbes and mites in the glands, potentially resulting in stagnation of the meibum and leading to the release of enzymes (activating inflammation). In turn, this may lead to qualitative changes in the tear film owing to an increase in the melting temperature of the meibum as it becomes more viscous. The modified flora is thought to induce an increase in the concentration of free fatty acids, secondary to increasing the activity of bacterial lipases, which may induce apoptosis of the ocular surface epithelial cells. The second circle shows how MGD may lead to a decrease in the lipid layer of the tear film, giving rise to hyperosmolarity of the tear film and inflammation – a combination that could induce enzyme activity, leading to keratinization of the meibomian gland ducts.

proposes an integrated aetiological hypothesis based on existing evidence in which MGD arises from any combination of six separate conditions: primary obstructive hyperkeratinization of the meibomian gland, abnormal meibomian gland secretion, eyelid inflammation, corneal and conjunctival inflammation and epithelial damage, microbiological changes (e.g. *Staphylococcus* sp., *Propionibacterium acnes* and *Demodex* sp.) and DED [1,7,9,15]. Hyperkeratinization of the meibomian glands causes obstruction, degenerative gland dilation, and atrophy. It is proposed that hyperkeratinization can be exacerbated by changes in normal meibomian lipids and the generation of free fatty acids, which may result from the release of lipid-degrading enzymes (esterases and lipases) by pre-existing commensal bacteria of the eyelids, causing epithelial irritation that promotes inflammation and stimulates further hyperkeratinization with cicatricial changes [12,16,17]. In the aforementioned sequence of events, the growth of commensal bacteria, and the consequent release of lipid-degrading enzymes, is postulated to occur as a result of the stagnation of meibum following meibomian gland obstruction [16]. Infection with commensal bacteria such as *Staphylococcus aureus* is an established pathogenic cause of chronic blepharitis, an inflammatory condition of the eyelid margin previously referred to synonymously with MGD but in recent years acknowledged as a related clinical condition that can develop in later stages of MGD, or independently [9,16]. *Staphylococcus aureus* is a commensal bacterium of skin and mucosa in the nose vestibule, but it can develop into an important opportunistic pathogen [18]. Increased bacterial growth associated with MGD-related blepharitis may arise from a different mechanism than that of meibum stagnation in MGD, but the downstream effects are proposed to manifest as inflammation and further hyperkeratinization [16]. Unlike chronic blepharitis, however, the pathogenic role of bacterial infection in inflammation associated with MGD remains to be clarified [16].

Skin diseases such as rosacea or seborrhoeic dermatitis also play a part in MGD pathophysiology, and recent evidence has shown that microbial and pathogenic mechanisms (along with neurovascular changes, chronic inflammation and dysregulation in immunity) may be involved in rosacea pathophysiology. Intestinal microbiota have been shown to play a role in the function of sebaceous glands, as significantly higher incidence rates of small intestine bacterial overgrowth (SIBO) have been identified in patients with rosacea compared with controls [19,20].

The high prevalence of MGD among normal patients presenting for routine vision testing was documented many years ago [21]. However, precise estimates of MGD prevalence are elusive, as the rates vary geographically, and until recently, a clear definition of MGD was lacking. Approximately 60% of Asian populations are reported to have MGD, but in Caucasians, the rate is less than 20% [7]. Prevalence is also affected by age, with reports of MGD in 33% of patients aged < 30 years and in 72% of patients aged ≥ 60 years in an Asian population [22].

Approximately 90% of patients with ocular rosacea (8–50% of all rosacea cases [23]) show eyelid changes (for example, inflammation of the lid margin [24]) that are similar to those observed in patients with MGD [10]. Despite the frequent association with MGD [23], ocular rosacea is often underdiagnosed by ophthalmologists [25]. The ability to differentiate between cases of MGD without dermatitis and rosacea-associated MGD is important, as the latter form has a worse prognosis [24].

3. The role of MGD in DED

One of the outcomes arising from the 2011 International Workshop on MGD was a clarification of the association between MGD and DED [7]. DED and MGD were reported in 11% and 35% of

patients, respectively, in a population-based study that used an array of subjective and objective tests, in addition to examination of the eyelid margins and meibomian gland, to identify ocular disease. Almost half of the patients with DED were found to have MGD, with the presence of MGD strongly associated with the symptoms and signs of DED, even when adjusted for age and gender [26]. The strength of the association between symptoms of MGD and DED has not been examined, although it is generally understood that there is marked symptom overlap between the two conditions [7].

In the healthy eye, the meibomian glands provide the meibum that forms the lipid layer of the tear film and from which the layer is replenished [9]. Given this substantial codependence between the tear film and the meibomian glands, differentiating MGD-related DED from other ocular surface diseases can be challenging [27]. On the other hand, tests such as the tear film break-up time (TBUT) have been effectively harnessed to diagnose evaporative DED and MGD-related DED through measurement of tear film instability, a core mechanism of DED that reflects an alteration in the tear film layer and, by extension, meibomian gland function, among other factors [9]. The International Workshop on MGD recommended a sequence of tests, including TBUT, ocular surface staining, Schirmer score and tear volume, to facilitate the differential diagnosis of MGD-related evaporative DED and aqueous-deficient DED [9]. In addition to these tests, examination of other innate mechanisms that underlie MGD and DED pathogenesis may be used to differentiate MGD-related DED from other forms of DED. For example, expression of acidic mammalian chitinase (AMCase) is increased in patients with MGD compared with patients with Sjögren's syndrome, while the proinflammatory matrix metalloproteinase 9 (MMP9) is expressed at higher levels in patients with Sjögren's syndrome than in those with MGD (although the expression in patients with MGD is still higher than that in the general population) [28,29]. While these preliminary data are encouraging, the effect of disease severity on marker levels is just one of the factors requiring further clarification with regard to the diagnostic value of AMCase and MMP9 in MGD-related DED. Conversely, MGD-related blepharitis can induce a chronic response of the ocular surface that makes it difficult to differentiate MGD from other forms of DED with a different pathogenesis, as the clinical features are comparable [30].

The relationship between MGD and DED is clearly illustrated in the vicious circle of DED, which indicates the central role of tear film instability [11]. An expanded version of the vicious circle elucidates the pathology of MGD and its relationship to DED (Fig. 1) [12,13]. The first circle illustrates the proposal that MGD, diagnosed by blockage/atrophy of meibomian glands, could lead to a proliferation of microbes and mites in the glands, potentially resulting in stagnation of the meibum and leading to the release of enzymes (activating inflammation) [16,28,31]. In turn, this may lead to an increase in the melting temperature as the meibum becomes more viscous. The modified flora is thought to induce an increase in the concentration of free fatty acids, secondary to increasing the activity of bacterial lipases, which may induce apoptosis of the ocular surface epithelial cells [29,32]. While the causal role of bacteria in MGD has not been conclusively established for all forms of MGD, there is evidence to support the importance of bacterial products (such as lipases) of *S. aureus* and *P. acnes*, for example, in the pathogenesis of MGD [16]. The role of *Demodex* mites in the pathogenesis of DED and MGD has not been proven or fully elucidated, although a recent confocal microscopy study highlighted an association between *Demodex* infestation (of the lower eyelid lash follicles and meibomian glands) and MGD in patients with DED that was not due to contamination [31]. The second circle shows how MGD may lead to a decrease in the lipid layer of the tear film, giving rise to hyperosmolarity of the tear film and inflammation – a

combination that could induce enzyme activity, leading to keratinization of the meibomian gland ducts. Microbial involvement (*P. acnes*) is implicated in a recently characterized inflammatory form of MGD, meibomitis-related keratoconjunctivitis (MRKC), that is frequently seen in younger patients and shares signs and symptoms with childhood ocular rosacea [33,34]. Systemic antimicrobials targeting *P. acnes* have demonstrated efficacy in MRKC, highlighting the potential importance of eradicating pathogenic bacteria in some forms of MGD [33,34].

4. Diagnosing MGD

MGD is a main cause of evaporative DED (also known as lipid-deficient DED) [3,35–37], although other pathogenic factors of evaporative DED include low blink rate; incomplete blinking; preservatives in topical ophthalmic medications; contact lens wear; ocular surface disease, including allergic eye disease; and disorders of the eyelid anatomy and function [17]. MGD also often exists in conjunction with aqueous-deficient DED [7,38]. The contribution of MGD to the severity of aqueous-deficient DED is unclear and requires further study [7]. It may be speculated from the proposed expanded vicious circle of DED (Fig. 1) that the clinical course of aqueous-deficient DED worsens with increasing severity of MGD. Diagnosing MGD can be problematic, as the symptoms are not specific to the disease, and, currently, questionnaires for assessing symptomatology are mainly directed towards aqueous-deficient DED. There is a need for a standardized clinical assessment and diagnosis of MGD that also includes the identification of MGD-associated sebaceous skin diseases. With this consideration, it is best to examine the clinical signs first. Much useful information is available from the 2011 report on the diagnosis of MGD [9], but newer diagnostic technologies are now emerging, and the topic of diagnosis needs revisiting. In clinical studies, the consistency of the diagnostic process remains poor, as was shown in a review that evaluated the interexaminer reliability of grading clinical variables associated with MGD [39]. The authors concluded that consistency ranged from fair to moderate across different measured clinical outcomes, namely acini appearance, gland dropout, eyelid debris and telangiectasias [39].

MGD can be asymptomatic or symptomatic, although with progression, asymptomatic MGD (detected by gland expression or meibography) may develop into symptomatic MGD [9]. In addition, MGD may develop alone or in association with ocular surface disease (OSDs) or it may occur secondary to other ocular disorders, including rosacea [9]. Early treatment during the asymptomatic stage of MGD may delay progression to the symptomatic stage and reverse the pathological events of MGD [9]. Symptomatic MGD may be detected via its key clinical signs [9], which include meibomian

gland dropout, as measured by the loss of acinar tissue (detected by meibography, whereby the meibomian glands are viewed in silhouette by transillumination through the everted eyelids, using a clearly defined technique to score the meibomian gland dropout), altered meibomian gland secretion (assessed by applying digital pressure to the tarsal plate) and changes in eyelid morphology (evaluated by slit-lamp microscopy). Several techniques are in current use for assessing meibomian gland morphology and function (Table 1).

Many of the clinical signs and symptoms of rosacea-associated MGD are similar to those of MGD alone [24]. However, in the absence of specific diagnostic criteria for rosacea-associated MGD, diagnosis is based on the consideration of MGD as a clinical component of ocular rosacea, whereby confirmation requires the presence of symptom criteria for the separate clinical conditions [24]. Rosacea-associated MGD may be identified by the presence of a number of features: foreign body sensation, dryness or itching, photosensitivity, telangiectasia of the lid margin, periorbital oedema, clinical signs of lid inflammation, chalazia and the presence of chronic staphylococcal infection as manifested by hordeola (styes) [25,40]. Whether rosacea-associated MGD is, by virtue of its terminology, a combination of the two clinical conditions or whether it represents a different form of MGD remains to be determined. Nevertheless, rosacea-associated MGD is commonly associated with a poorer prognosis than MGD alone [24].

Following an initial observation of the patient's face for signs of dermatological disease, a recommended diagnostic sequence for assessment of DED and MGD that follows the principle of performing the most invasive tests last should be used (Fig. 2).

- i. *Patient questionnaire.* While there are no specific questionnaires designed for the assessment of MGD, there are several that are currently used for assessing DED symptomatology: McMonnies, Schein, Canadian Dry Eye Epidemiology Study (CANDEES), Ocular Surface Disease Index (OSDI), International Sjögren's Classification, Women's Health Study, Dry Eye Questionnaire (DEQ), Ocular Surface Disease – Quality of Life (OSD-QoL) and Impact of Dry Eye on Everyday Life (IDEEL) [17]. A newer questionnaire, Standard Patient Evaluation of Eye Dryness (SPEED), has fewer questions and easier interpretability than the OSDI and seems to correlate better with the parameters of evaporative DED, while OSDI values have a better correlation with aqueous-deficient DED [41]. See Table 2 for further information on these questionnaires. In addition, clinical scorecards can be used to grade the features and severity of rosacea [40].
- ii. *Tear break-up time.* TBUT is a surrogate indicator of tear film stability. Low scores (<10 s) can indicate an inadequate

Table 1
Methods for assessing meibomian gland function [9,126].

Technology	Function
Meibomian gland expression	Application of pressure (digital or with an instrument) to eyelids to quantify and qualify meibomian gland expression
Meibometry	Quantification of the amount of lipids at the eyelid margin by blotting lipids onto a tape applied to the eyelid
Keratography	Permits visual assessment of the topography of the corneal surface and non-invasive TBUT
Newer techniques	
Meiboscopy/meibography	Allows observation of the morphology of meibomian glands and quantification of meibomian gland dropout by clinical observation or photodocumentation Visualization of the meibomian glands can be by transillumination (through the eyelid) or use of infrared light and camera (non-contact)
Interferometry	Provides visual analysis of the lipid layer of the tear film using broad-spectrum white light interferometry
<i>In vivo</i> confocal laser microscopy	High-resolution scans enable measurement of acinar density (number of glands/mm ²), mean acinar diameter and visualization of morphological changes of the glands
Evaporimetry	Detects real-time changes in tear evaporation rates and examines tear film stability

TBUT, tear film break-up time.

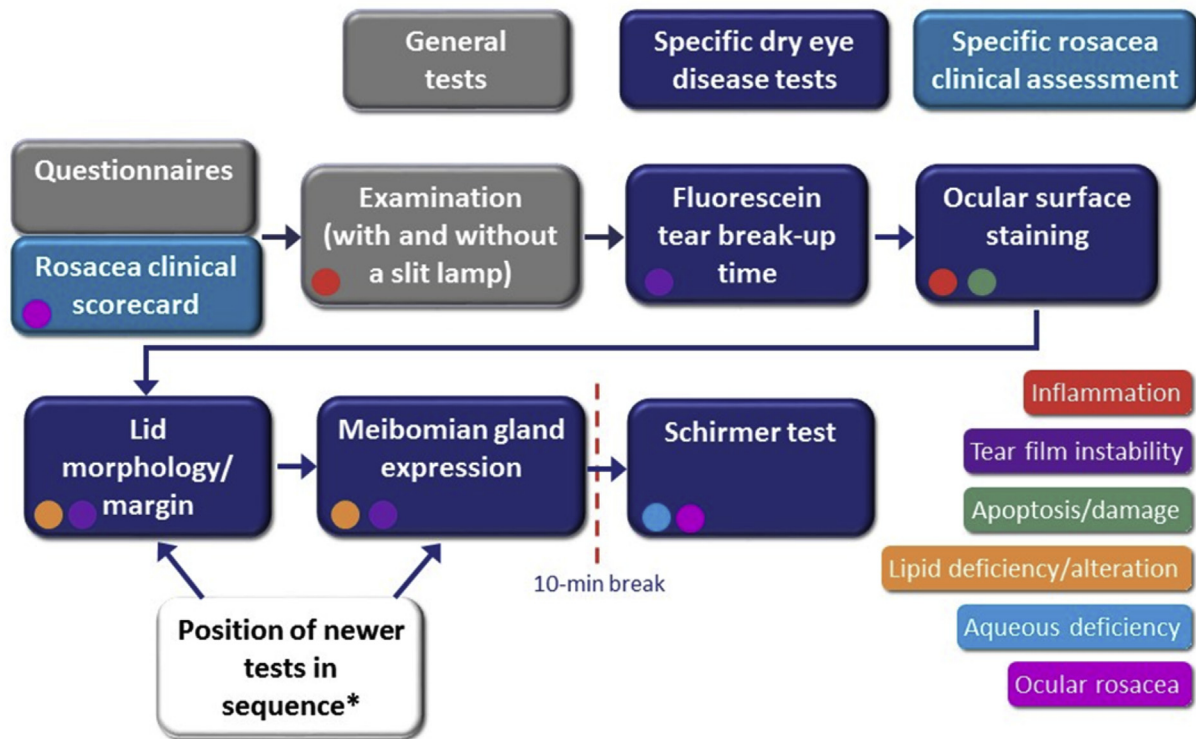


Fig. 2. A practical diagnostic sequence for meibomian gland dysfunction alone or in the presence of aqueous- or lipid-deficient dry eye disease. *Refer to Table 1 for further information on technologies to assess meibomian gland dysfunction. Based on the International Dry Eye Workshop 2007 [17] and OCEAN panel expert opinion.

balance between the mucoaqueous and lipid layers of the tear film and are often related to a compromised lipid layer owing to meibomian gland dysfunction, although this can also result from a deficient aqueous layer [9]. TBUT score does not provide a differential diagnosis between MGD and DED [42].

- iii. *Ocular surface staining.* Ocular surface damage is a common consequence of tear film instability associated with MGD, although it is not necessarily diagnostic to MGD. It can be quantified by grading the staining of the cornea (using fluorescein) and conjunctiva (using lissamine green) [9]. In the clinical experience of the authors, staining along the upper and lower lid margin more is likely to be associated with MGD or some form of blepharitis, and central staining is more likely to be related to aqueous-deficient dry eye.
- iv. *Eyelid morphology/margin examination.* Along with a low TBUT, compromised eyelid morphology (where the eyelid margin is irregular, not the eyelid itself) is classically suggestive of MGD [43]. Examination should include an assessment of the eyelid margin (looking for thickening, telangiectasia/vascularity and notching) and orifices (checking the number and condition of the eight central glands of each eyelid) [9,44]. In early MGD, subtle morphological changes may not be apparent upon physical examination. Blackie et al. have described nonobvious obstructive MGD (NOMGD), which seems to be the precursor to obstructive MGD [45]. In NOMGD the classical clinical signs of MGD (e.g. irregular lid margin, lid margin thickening, and meibomian gland orifice pouting) are not apparent and the diagnosis is made on the basis of meibomian gland expression (see point v. below) [45].
- v. *Meibomian gland expression.* The presence of MGD can be confirmed by assessment of meibomian gland expression

(quantity, quality and expressibility of meibum) and gland dropout [9,44]. Indeed, the only method to determine whether a specific meibomian gland is functional and capable of providing secretion is to observe the secretion expressed from that gland [9]. Physical force is applied to the eyelid either by digital pressure, or with the use of a hand-held instrument to provide standardized force to the eyelid [9]. The eyelid is simultaneously observed under suitable magnification to assess the gland expressibility, lipid volume, and lipid quality [9].

- vi. *Schirmer test.* This should ideally be the final test performed, as it can affect the results of the ocular surface staining tests. A Schirmer score ≤ 5 mm/5 min (without anaesthesia) indicates dry eye severity levels of 2–3 and is strongly indicative of aqueous-deficient DED [17,46], while patients with lipid-deficient DED may have reflex excessive or moderately reduced tear production [30]. By contrast, reduced tear production has also been observed in rosacea-associated MGD [47]. Therefore, the Schirmer test may be useful in differentiating between primary MGD (usually normal Schirmer test result) and conditions associated with reduced tear production and stability, such as rosacea associated with MGD [24], ocular rosacea [48–51] and aqueous-deficient DED, but it cannot be considered as a robust screening test because there are situations where MGD and aqueous-deficient DED coexist.

5. Emerging technologies for the diagnosis of MGD

While the diagnostic test sequence described above offers ophthalmologists practical guidance on the best approach to identify MGD and MGD-related diseases using current tests and

Table 2
Patient questionnaires.

Questionnaire	Description	Pros	Cons
Canadian Dry Eye Epidemiology Study (CANDEES) [127]	13 questions: environmental triggers, symptom severity, allergies	Simple and fast	Tool designed for epidemiological studies and not for clinical assessment Includes demographic data as well as QoL symptoms
Dry Eye Questionnaire (DEQ) [128]	23 main questions: impact of symptoms on daily life, severity of symptoms, medications 68 questions in total	Comprehensive	Time-consuming Requires lexical skills
Impact of Dry Eye on Everyday Life (IDEEL) [129,130]	57 items in 3 modules: impact of dry eye on daily life, treatment satisfaction, symptoms Validated by FDA PRO instrument development guidelines	Very comprehensive High efficacy for exploring new therapies Adequate for clinical trials	Very time consuming to complete Not adapted for daily clinical practice
International Sjögren's Classification [131,132]	Criteria based on Sjögren's International Collaborative Clinical Alliance 3 questions	Quick and easy	Not developed specifically for DED
McMonnies [133,134]	14 questions carried out by the patient Initial screen test for presence/absence of dry eye	Mix of several types of questions Validated Suitable as a screening questionnaire	Not adapted for clinical trials May not distinguish between mild, moderate or severe DED
Ocular Surface Disease – Quality of Life (OSD-QoL) [135,136]	26 questions (score 0–100): including daily activities, professional activities & handicap, fear of future/vision loss, emotional well-being and mood	Adaptable to several types of OSD Has been shown to provide relevant information	Not only focused on DED Questions not validated in English
Ocular Surface Disease Index (OSDI) [137,138]	12 questions that assess dry eye symptoms 3 subsections on environmental triggers, ocular symptoms and vision-related function Validated	Simple and fast to answer Effective discrimination between mild, moderate or severe DED Possibility of declaring some questions as non-adapted to the situation of the patient	Covers only 1 week of symptoms
Schein [139]	Developed to test DED in elderly cohort 6 questions with 4 grades of answers	Simple to use	3 questions in the same field No clear definition of the frequency of grading
Standard Patient Evaluation of Eye Dryness (SPEED) [140]	8 questions Includes questions on severity Very quick to use	Covers 3 month period prior to completing	Does not contain questions regarding task and environmental triggers
Women's Health Study [141,142]	11 questions	Includes QoL questions that determine effect of DED on daily living	Requires more validation as is poorly described in literature

methodologies, there are several emerging technologies that show promise for improving the diagnostic procedure (Table 1). However, there is still a challenge to find a single reproducible, reliable and well-accepted test that can be used in general practice. This need has encouraged many researchers and companies to develop a number of increasingly sophisticated instruments as diagnostic tools that can be adapted for screening for MGD. Some of the most promising tools are outlined below and have been summarised in Table 1.

5.1. Interferometry

Interferometry may be used to visually analyse the lipid layer of the tear film [52,53]. One of the first interferometers to be developed was the Tearscope® tear film analysis device, which was launched in 1997 by Keeler Ltd (Windsor, UK) [54,55]. Initially developed to measure TBUT, the Tearscope® projects a cylindrical source of white fluorescent light onto the tear film lipid layer (TFLL), which can then be assessed by use of the interference images obtained [56,57]. Comparison of the images allows grades based on the uniformity and colour of the lipid film to be assigned. Its use for assessing the lipid film has been shown to be objective, with good inter-observer correlation [56,57].

TFLL interference patterns can also be captured using the DR-1

camera (Kowa, Nagoya, Japan); severity can be assessed according to the Yokoi dry eye grading system – grade 1, somewhat grey colour, uniform distribution; grade 2, somewhat grey colour, non-uniform distribution; grade 3, a few colours, non-uniform distribution; grade 4, many colours, non-uniform distribution; grade 5, corneal surface partially exposed [35,58].

More recently, the LipiView® interferometer (TearScience Inc., Morrisville, NC, US) has been developed. This device exploits the principle of broad-spectrum white light interferometry (<http://www.tearscience.com>). The patient's eye is illuminated with light directed at the corneal surface; the light passes through the tear film and is reflected into a camera, forming an interference pattern called an interferogram. The LipiView® interferometer measures the lipid layer thickness of a defined area of tear film and captures the blink profile during a designated time interval [59]. A positive correlation between TFLL thickness and expressible meibomian glands suggests that a low lipid layer thickness indicates a high probability of MGD. Quantitative results for TFLL behaviour can be obtained by employing the dynamic lipid layer interference patterns (DLIP) test [60]. The DLIP test measures the interference pattern of the lipid layer on the central area of the precorneal tear film between blinks, allowing for an evaluation of the elastic properties of the lipid layer and its ability to produce a stable interference pattern. Results demonstrated a significant difference

between normal (21 ± 12 blinks before a change) and dry eyes (3.2 ± 1.5 blinks before a change), $p < 0.001$. Sensitivity and specificity tests indicated that measurements should be taken after 6.5 consecutive blinks in order to obtain the most consistent and reliable results [60].

A few years ago, a number of studies demonstrated that interferometry was a useful tool in diagnosing both the presence and severity of DED [61]. However, its value as a screening test for MGD has now been demonstrated by Eom et al. in a study that differentiated between 25 individuals with normal eyes (control group) and 30 patients with obstructive MGD by measuring and comparing the thickness of the TFLL. The lipid layer was shown to be significantly thicker in the control group vs the group with obstructive MGD ($p = 0.028$) [62]. In a separate study of 110 patients (199 eyes) from a DED population, there was a significant correlation between the number of expressible meibomian glands and the lipid layer thickness, suggesting a higher probability of MGD in patients with a low lipid layer thickness [59].

5.2. Non-contact meibography

Meibography is a specialised technique developed solely for directly observing the morphology of meibomian glands *in vivo* [63]. Traditional meibography (developed in the late 1970s) observes the structure of meibomian glands in silhouette by illuminating the eyelids from the skin side via a probe applied directly to the eyelid [64,65]. While providing highly useful images for many years, the technique suffered from a number of limitations; these included a lack of documentation and detailed analysis of the technique and the need to take several images in order to form a composite panoramic image of meibomian gland morphology [66]. It was also often very uncomfortable for the patient owing to the heat, brightness and sharpness of the probe [66]. Recently, non-invasive methods of meibography have been explored that avoid causing the patient discomfort and permit simpler observation of the upper and lower eyelids [64,65]. The technique, as seen for example with the Topcon BG-4M Non-Contact Meibography System (Topcon Medical Laser Systems, Inc., Santa Clara, CA, US), uses a slit-lamp biomicroscope and video camera with an infrared filter. It enables detection of meibomian gland dropout, shortening, dilation and distortion. It is a less time-consuming technique than the conventional contact methods, easier to use and more patient friendly [65]. Recent advancements to the technology now include mobile, hand-held, pen-shaped systems with an infrared LED fixed to the camera, which enable videos and images to be captured that are comparable in quality to previous meibography systems [67]. These portable devices, such as the Meibom Pen (Focus Corporation, Tokyo, Japan), eliminate the need for a slit lamp and have the potential to become a common feature in clinical practice. Arita et al. proposed a scoring system (meiboscore) in which each eyelid is examined for meibomian gland loss and scored from grade 0 (no loss of meibomian glands) through grade 3 (the area of loss more than two thirds of the total meibomian gland area [65]).

Many studies have previously confirmed the use of meibography for the diagnosis and evaluation of MGD [14,43,44,68]. Non-contact meibography using a standard infrared video security camera was examined in 17 patients, and the extent of meibomian gland loss was measured by digital image analysis [69]. A significant correlation between meibomian gland loss and lipid layer pattern, non-invasive TBUT and OSDI was shown, suggesting that this technique may have diagnostic value. A recent evaluation of meibomian gland atrophy using non-contact infrared meibography concluded that examination of just the lower eyelid is probably sufficient for the evaluation of meibomian gland atrophy and that meiboscore correlates with expressible meibomian glands and

TBUT, suggesting that in patients with detectable meibomian gland atrophy, meibomian gland function is impaired. Furthermore, meibography alone seems insufficient as a single test and has to be interpreted in the context of other clinical parameters (e.g. expressible glands and TBUT) for the diagnosis of MGD [70]. Objective analysis of the images derived from non-contact meibography is also being developed using advanced software [71]. An objective method such as this would permit more subtle morphological changes in the meibomian gland to be evaluated, as well as the monitoring of treatment response and dropout associated with non-responders of meibomian gland-targeted treatment.

In addition to evaluating non-invasive TBUT (see next section), the Oculus Keratograph 5M is able to examine the meibomian glands, tear meniscus height and lipid layer. The Keratograph 4 (Oculus) was used to image the meibomian glands of 37 participants to determine morphological changes in both the upper and the lower eyelids [72]. Differences in the meibomian gland dropout score were observed between patients with and without MGD. These differences were observed whether subjective ($p = 0.0004$) or digital ($p = 0.001$) grading scales were used [72].

5.3. Non-invasive TBUT using keratography

Keratography permits visual assessment of the topography of the corneal surface, allowing for an analysis of tear film stability by comparing the irregularities in recorded images. A number of studies have been published that have investigated the non-invasive technique for its clinical usefulness in screening for DED and MGD [72,73].

Non-invasive TBUT using a keratograph was clinically assessed in 100 patients using either the Oculus Keratograph (Oculus, Inc., Lynnwood, WA, US) or the standard Keeler Tearscope (Keeler Ltd, Windsor, UK) [73]. The Oculus Keratograph was found to detect very early tear film changes, which may be an advantage, but it recorded significantly lower non-invasive TBUTs than the Tearscope [73]. The objective measurement of tear break-up with the Oculus Keratograph may have clinical use by providing information on the location of multiple breaks, the area covered and any film reformation [73].

The Oculus Keratograph 5M (<http://www.oculus.de>) represents the latest technology in keratographs. It is an advanced, non-contact corneal topographer with integrated keratometer and colour camera. Multifunctional ophthalmic instruments such as this are able to use an inbuilt infrared camera for meibography [71].

There are many other instruments available that employ the technique of measuring non-invasive TBUT using keratography, and this list is not intended to be comprehensive, but only to highlight the technology as one that shows potential for improving the diagnosis of MGD.

5.4. *In vivo* confocal laser microscopy

In vivo confocal laser microscopy is a contact technique that is employed in many clinical areas and has also been trialled in the examination of meibomian glands. With the ability to take multiple images, *in vivo* confocal laser microscopy allows extensive examination of the subject of interest, including diffuse disease. It can be used to examine acinar density and diameter, secretion reflectivity and periglandular inflammation for their diagnostic values in patients with MGD [22,74,75]. The technique involves scanning the inverted eyelid and meibomian glands while moving the applanating lens along the eyelid length. The procedure requires an experienced examiner, can take up to 10 min, is considered to be more intrusive than meibography and requires the use of topical anaesthesia.

The screening potential of *in vivo* confocal laser microscopy for MGD was examined in a prospective study of 20 patients with MGD compared with 15 controls, using the parameters of acinar unit density and diameter [22]. The study demonstrated that patients with MGD had an increased acinar unit diameter with decreased mean acinar unit density compared with the control group ($p < 0.05$, for both measures) [22]. Both parameters were significantly associated with meibomian gland dropout and meibomian gland expressibility grades ($p < 0.05$) [22]. The images also indicated that enlargement of the acinar units was due to inspissation of meibum secretions and glandular atrophy with periglandular fibrosis [22].

Confocal microscopy also has the potential to diagnose MGD with high sensitivity and specificity [76]. A prospective, controlled study of 20 patients with MGD and 26 controls found that all confocal microscopy parameters correlated strongly with tear functions, ocular surface staining, meibomian gland expressibility and dropout grades.

Finally, this emerging technology has proved to be useful as a diagnostic adjunct tool for *in vivo* examination of meibomian glands [75]. Confocal microscopy may be of great value in imaging resident *Demodex* mites in the meibomian gland orifices [31]. Although a causal role of *Demodex* infestation in MGD pathology has not been established, confocal microscopy has identified low frequencies of *Demodex* mites in the eyelids and glands of healthy subjects, whereas levels are increased in the skin, lash follicles or even meibomian glands of patients with MGD-related DED, blepharitis and rosacea [31,77]. When such observations are considered together with reports of successful eradication of *Demodex* mites in patients with rosacea following targeted antimicrobial treatment, a pathogenic role for *Demodex* infestation in ocular disease cannot be wholly discounted [77].

6. Recommendations for managing MGD

Optimal management of MGD is important as the clinical challenge of MGD goes beyond the ocular surface. For example, MGD is implicated in unfavourable outcomes after various surgical procedures [27]. Active blepharitis may increase the presence of bacteria on the ocular surface and pose a risk for the development of postoperative endophthalmitis [78]. Additionally, MGD can cause serious corneal disease if progression to permanent gland atrophy occurs [79].

The principal goal of all treatments of MGD is to increase the quality and quantity of meibomian expression and thus improve patient symptoms, with early treatment being of particular importance [6]. Existing treatment algorithms for MGD recommend therapies according to the severity of the condition, beginning with eyelid hygiene and progressing to the addition of topical lubricants (lipid-containing sprays, tears or ointments); topical and systemic antibiotics with anti-inflammatory properties, such as macrolides and tetracyclines; anti-inflammatory agents or omega-3 fatty acid dietary supplementation; and topical steroids [1,80]. Some of the traditional and effective approaches to managing MGD are outlined below, along with a review of some of the emerging treatment options and devices that are available.

6.1. Eyelid hygiene

Eyelid hygiene is the cornerstone of MGD treatment and consists of two components: eyelid warming and eyelid massage [80]. The improvement in symptoms of MGD with eyelid hygiene was recently confirmed in a randomized controlled trial [81]. It is recommended that patients with MGD apply hot compresses for 5 min in the morning and evening to loosen the meibum, followed by

massage of the closed eyelid. The importance of eyelid hygiene in the management of MGD is highlighted by the potential involvement of microbes, e.g. *Staphylococcus* sp., *P. acnes*, *Bacillus oleronius* and the *Demodex* mite, in the pathology of MGD-associated DED (Fig. 1). As previously discussed, these microbes are thought to contribute to the changes in meibum secretion that result in an increased melting temperature and further inflammation [16]. There are several preparations available for eyelid cleansing, some of which contain tea tree oil, which has been shown to be effective in eradicating *Demodex* mites (although the pathogenic role of *Demodex* mites in MGD is uncertain) [82].

Application of warmth to the meibomian glands is believed to provide benefit by melting the meibomian lipids. Some studies have suggested that MGD can cause meibomian glands to produce secretions with reduced levels of lipids, esters and free sterols compared with those produced by normal meibomian glands [83]. Meibum in patients with MGD has a higher melting temperature (35 °C) compared with that in normal control individuals (32 °C) and is more stagnant and viscous [80]. Thus, a therapy that involves warming the eyelid to melt the pathologically altered meibomian lipids could lead to an improvement in their secretion [80]. After warming, effective massaging of the eyelids can be achieved by applying traction on the lateral canthus to keep the eyelids in position followed by mildly compressing the eyelids upwards or downwards with a cotton bud, starting from the nasal canthus and moving laterally toward the lateral canthus [80].

While eyelid warming and eyelid massaging have been shown to be effective in the management of MGD, these methods are often time consuming and labour intensive, and can lead to patient compliance problems [84]. Thus, in order to standardise and simplify the treatment, a number of different devices have been developed. In a study of 25 patients with MGD-related evaporative DED, the eyelid-warming device MGDRx Eyebag® (The Eyebag Company, Halifax, UK) significantly improved ocular symptomatology, non-invasive TBUT, lipid layer thickness, osmolarity, and meibomian gland dropout and function [85]. Similarly, in another study of 73 patients with MGD, the eyelid-warming device Bleephasteam® (Laboratoires Théa, Clermont-Ferrand, France) was used twice a day for 3 weeks and was found to significantly improve the symptomatology visual analogue scale score from 63.1 (baseline, Day 0) to 41.9 on Day 21 ($p < 0.001$) [86]. A non-wet eyelid-warming pillow, Azuki no Chikara (Kiribai Chemical, Osaka, Japan; currently available only in Japan), used repeatedly in patients with MGD resulted in significant and lasting improvements in superficial punctate keratopathy score, TBUT, meibum grade, tarsal conjunctival temperature and meibomian gland area compared with baseline values [87]. A dual-paddle heating device has been developed (MiBo Thermoflo; MiBo Medical Group, Dallas, Texas, US) which can warm, massage, and empty clogged Meibomian glands on both upper and lower lids simultaneously; patient symptoms were improved in initial non-randomized studies [88].

Of the new technologies that are now emerging to improve upon traditional eyelid hygiene techniques, the LipiFlow® system (www.lipiflow.com) has shown some promise. It is a device akin to a scleral shell inserted under the eyelid combined with a second outer shell resting on the outside of the lid. While the inner shell provides heat to the tarsal conjunctiva of both the upper and the lower eyelids for 12 min, the outer shell simultaneously applies a massaging pressure to express the meibomian glands [4,59]. A recent study compared the thermal pulsation device LipiFlow® with an eyelid-warming device (MeiboPatch®) for the management of MGD in 30 patients [89]. Both techniques increased the number of functional meibomian glands at Month 3, but LipiFlow® provided more rapid improvement within the first month of treatment.

In a recent prospective, randomized, controlled, crossover,

observer-masked clinical trial, manual eyelid hygiene was compared with the automated thermodynamic treatment (LipiFlow[®]) for the management of MGD in 31 patients [81]. In the first group, the patients received a detailed explanation once on how to perform manual eyelid hygiene, including warm compresses and subsequent massage, and were advised to apply this for the subsequent 3 months, while the second group received a single LipiFlow[®] treatment as an in-office procedure. Only the group receiving the automated treatment demonstrated a significant improvement of symptoms; however, both groups showed an increase in the number of expressible, functional glands. Since it was only possible to mask the observer, a placebo effect on symptoms could not be ruled out. The same authors performed an uncontrolled follow-up analysis of 26 patients after 6 months, in particular to correlate the efficacy of the automated treatment with meibomian gland atrophy using meibography and meiboscore (a measure of meibomian gland loss) [90]. When compared with baseline, at the 6-month follow-up patients receiving a single LipiFlow[®] treatment showed reduced symptoms, a higher number of expressible meibomian glands, increased TFL thickness, reduced bulbar redness and a reduced number of eyelid margin parallel conjunctival folds. The reduction of symptoms and increase of expressible meibomian glands were significantly lower in patients with severe meibomian gland atrophy (meiboscore score of 6), as visualised by meibography; therefore, these patients should be regarded as potential non-responders.

Finally, a novel technique to address lid margin irregularities and obstruction of the gland orifice is the surgical removal of damaged or infected tissue to aid the healing potential of the remaining healthy tissue (debridement). In a small, open-label study ($n = 28$) to test its effectiveness in patients with MGD who also showed a thickened line of Marx, the procedure was shown to provide significant symptom relief and improvement in meibomian gland function ($p = 0.0007$) [91]. A less invasive method of microexfoliation of the lid margins is available with the BlephEx device (Scope Ophthalmics, West Sussex, UK), which utilises a rapidly rotating microspunge to remove lid debris and microbial biofilm from the lid margins [92].

Intense pulsed light (IPL) near the eyelid has been proposed to improve MGD by causing closing of the abnormal blood vessels, which are thought to secrete inflammatory mediators that cause malfunction of the glands. A 6-year retrospective review of MGD patients treated with IPL ($n = 91$) reported a significant improvement in TBUT, and >90% of patients had physician-judged improvements in meibum and lid margins [93]. These novel techniques are not yet validated, and require confirmation of benefit with additional controlled clinical trials.

6.2. Artificial lubricants

The addition of a lipid component to artificial lubricants is proposed to replenish the lipid layer of the tear film [80]. These artificial lubricants have been shown to stabilise the TFL, have a long residence time in the tear film, reduce the tear evaporation rate and improve the signs of MGD [80,94]. The lipids used in these artificial lubricants are as follows:

- Cationorm[®] (Santen) – mineral oil [95].
- Optive Plus[®] (Allergan) – highly pure castor oil [96].
- Soothe[®] XP (Artelac[®] lipids in Germany; Bausch & Lomb) – light mineral oil, mineral oil [97].
- Systane[®] Balance (Alcon) – polar phospholipid surfactant (dimyristoylphosphatidylglycerol) and mineral oil [98].

Although patients with MGD were not specifically enrolled, a

recent study in 1209 patients with DED found that Optive Plus[®] was an effective treatment in a subset of the patient group with lipid-deficient DED [96].

Moreover, lipid-containing eyelid sprays such as Tears Away (OCuSOFT liposomal spray have been shown to relieve the symptoms of DED and were favoured over an eye gel preparation [94,99]. The phospholipid liposomal spray is applied to the closed eyelids, and the liposomes migrate, via the lid margins, into the tear film [100]. Notably, a single application of lipid-containing spray significantly increases tear film stability up to 90 min post treatment [100].

EvoTears[®] (also known as NovaTears[®]; Ursapharm GmbH/Novaliq GmbH) has recently been launched in Europe. EvoTears[®] contains a single ingredient: perfluorohexyloctane (F6H8), a novel substance from the family of semifluorinated alkanes (SFAs). Preservatives are not required in EvoTears[®] because it is a completely non-aqueous solution, meaning that microbial growth is not possible [101]. In a 6-week observational study of 30 patients with evaporative DED, EvoTears[®] significantly improved corneal staining, Schirmer scores, TBUT and OSDI scores from baseline [101]. During this study, three patients experienced mild-to-moderate hypersensitivity to EvoTears[®] and stopped treatment, after which they recovered fully [101]. Two further observational studies are currently recruiting (NovaTears[®]; www.clinicaltrials.gov).

In patients with a mixed aetiology of MGD and aqueous-deficient DED, artificial tears address problems common to both conditions; through mechanisms such as reduction of hyperosmolarity, reduced friction on blinking, spreading of the TFL and dilution of inflammatory cytokines in the tears, artificial tears may reduce proinflammatory stimuli [80].

6.3. Antibiotics and anti-inflammatory drugs

Antibiotics are commonly used in the treatment of MGD to reduce the presence of pathogens that are associated with, but not necessarily causal of, MGD [80].

Topical antibiotics commonly used to treat MGD include bacitracin, fusidic acid, metronidazole, fluoroquinolones, macrolides (including azithromycin) and tetracyclines [80]. Despite the fact that the role of bacteria in the pathophysiology of MGD remains uncertain, topical antibiotics (e.g. azithromycin) appear to be effective and well tolerated when used in the treatment of MGD [102]. Azithromycin, a broad-spectrum macrolide antibiotic, has anti-inflammatory properties in addition to antibacterial action and is the most commonly prescribed MGD treatment in the US [1]. However, there are few clinical studies of azithromycin in patients with MGD. The mechanism for its anti-inflammatory activity is not completely understood, but it is thought to block the activation of nuclear factor-kappa B, leading to a decrease in some of the inflammatory cytokines such as interleukin-6 and -8 [103]. It has also been reported to inhibit the production of proinflammatory mediators by acting directly on the corneal epithelial cells [104], and it increases expression of the anti-inflammatory transforming growth factor β 1, as evaluated by eyelid margin and conjunctival impression cytology, which may contribute to the anti-inflammatory activity of azithromycin in MGD [105]. Azithromycin has also been shown to restore the composition of meibum to a near-normal state, probably through an antilipase effect [106].

Systemic tetracycline derivatives such as oral doxycycline (slow-release 40 mg doxycycline or 40–100 mg/day for 6–12 weeks) are often preferred in the management of rosacea and MGD, mainly for anti-inflammatory and lipid-regulating properties rather than antimicrobial effects [80]. Prevention of proinflammatory free fatty acid release through suppression of lipase production by

S. epidermis and *P. acnes*, and, to a lesser extent, *S. aureus* at the eyelid margin, underlies the predominantly anti-inflammatory rather than antimicrobial action of tetracycline at low systemic doses [80]. It is important to note that tetracycline should not be administered to children younger than 8 years of age.

6.4. Cyclosporine

Cyclosporine A is a highly specific immunosuppressant agent that primarily affects the action of T lymphocytes [107]. Topical cyclosporine has been successfully used in the management of DED for many years, and its indication has now been extended to the treatment of MGD, where it appears to provide considerable benefit [1,108,109]. Two small studies in 2006 provided contradictory evidence on its efficacy, which may be due in part to the complex way that cyclosporine treats MGD [108,110]. In a comparison between topical cyclosporine 0.05% and placebo for the treatment of MGD, cyclosporine decreased meibomian gland orifice inclusions (plugging) and improved the objective signs of MGD; however, there was no improvement in symptoms over placebo [108]. Conversely, in a 12-week comparison of topical cyclosporine 0.05% and tobramycin 0.3%/dexamethasone 0.1% in patients with posterior blepharitis, cyclosporine provided significant improvement in signs, symptoms and tests that included eyelid health, Schirmer scores, TBUT, meibomian gland secretion quality and symptoms of blurred vision, burning and itching [110]. More recently, in a 3-month study of 70 patients with symptomatic MGD and unstable tear film, cyclosporine A 0.05% was shown to improve mean OSDI, invasive and non-invasive TBUT, eyelid margin inflammation and meibomian gland expressibility [109].

These results are encouraging; however, there is a clear unmet need for further studies of topical cyclosporine in the treatment of MGD and also ocular rosacea [29,80]. Moreover, there is some debate surrounding the optimal cyclosporine concentration, with some physicians believing 0.5% cyclosporine to be more efficacious than 0.05% in MGD. To date, no study has directly compared the efficacy and safety of 0.5% with 0.05% cyclosporine in MGD.

6.5. Omega-3 dietary supplementation

In a randomized, placebo-controlled, masked trial, omega-3 dietary supplementation was shown to improve overall OSDI score, TBUT and meibum score in patients with MGD and blepharitis [111]. Data suggest a beneficial role for oral supplementation with omega-3 essential fatty acids in improving the signs and symptoms of MGD [1,80,112]. Further research is required to fully understand the underlying mechanisms, likely involving non-specific anti-inflammatory properties and/or influence on the fatty acid composition and lipid properties of meibum [111,113–115].

6.6. Topical corticosteroids

Topical corticosteroids may be used for acute episodes of inflammation or to manage inflammatory complications of MGD [80]. Their effectiveness was demonstrated in a study of 32 patients with DED [116]. After 30 days of treatment, both the symptom severity scores and the expression of inflammatory markers (e.g. human leukocyte antigen II) in the conjunctival epithelial cells were reduced [116].

Although there is no published evidence for the long-term use of corticosteroids for the management of MGD, long-term corticosteroid use is not usually advised as it may lead to complications such as cataract formation, infections and elevation in intraocular pressure (of up to 60%) [80,117]. However, topical

glucocorticosteroids should not be used on cutaneous rosacea lesions associated with MGD because of their tendency to aggravate rosacea [118].

6.7. Surgical options

Surgical options for MGD generally involve treating the complications of MGD, such as conjunctivochalasis, entropion, ectropion and horizontal eyelid laxity, rather than the primary disease [80]. Intraductal meibomian gland probing removes meibomian gland secretions by mechanically opening and dilating the meibomian gland orifice and duct [119]. This technique is still controversial but was shown to be effective in relieving the symptoms of obstructive MGD, with 95% of patients experiencing postprocedure relief and 100% of patients experiencing relief 4 weeks following the procedure. Participants are currently being recruited for a randomized, double-blind trial (NCT02256969) investigating the efficacy of intraductal meibomian gland probing compared with a sham procedure in patients with refractory MGD [120].

7. Recommendations for managing rosacea-associated MGD

Treatment of rosacea-associated MGD should not be limited to eyelid hygiene, topical medications or dietary supplements. Oral doxycycline is highly effective for the management of ocular rosacea [121]. Using the anti-inflammatory potential of doxycycline, recent recommendations favour a long-term treatment of ocular rosacea of at least 6 months and tapering dosage down slowly depending on clinical improvement [122]. Its effectiveness was shown in a study of 39 patients with ocular rosacea associated with signs of ocular disease, such as telangiectasia and MGD. Doxycycline both improved ocular disease and increased TBUT [123]. Doxycycline monohydrate 40 mg is indicated for the reduction of papulopustular lesions in adult patients with facial rosacea [124].

Additionally, given the putative role of SIBO in the pathophysiology of rosacea [20,125], optimal management of rosacea-associated MGD should include oral antibiotics as well as topical anti-inflammatory agents. In a study to test the effectiveness of oral rifaximin therapy for rosacea patients with SIBO (10 days' treatment), it was demonstrated that the reduction of SIBO led to an almost complete regression of cutaneous lesions in patients with rosacea, which was maintained for at least 9 months [20]. In a separate study of patients with rosacea and SIBO, 14 days of treatment with oral rifaximin led to a marked improvement in rosacea symptoms in 46% of patients, and marked improvements in all four patients included with medicine-refractory ocular rosacea and SIBO [19]. Further studies are required to explore the effect of oral rifaximin therapy, as well as novel therapies such as the BiphEx device and IPL (see Section 6.1), on the ocular symptoms of rosacea-associated MGD.

8. Conclusion

MGD and MGD-associated diseases are widespread, chronic conditions that can often be overlooked in the clinic. Symptoms, which include ocular burning, irritation, itching, dryness and foreign body sensation, are generally exacerbated by factors that are part of everyday life, such as computer use, air conditioning and indoor heating. Equally, these symptoms are common complaints for a number of ocular surface diseases that include anterior blepharitis, ocular allergies, aqueous-deficient DED and evaporative (or lipid-deficient) DED. Many of these diseases overlap and patients may have a hybrid type of DED that is both aqueous deficient and involves dysfunction of the meibomian glands. Consequently, diagnosis of the correct ocular surface disease can be challenging,

with patients often having to visit a physician many times in order to ascertain the underlying cause of the complaint. Patients often discover that their quality of life is significantly reduced by the disabling symptoms; therefore, they can be frustrated by the perceived lack of a clear diagnosis and lack of improvement during treatment. Consequently, it is important to provide accurate and reliable evaluation tests in order to diagnose their condition as early as possible to ensure that they are offered the most appropriate treatment and management program.

This review highlights the complexities of current resources for the diagnosis of MGD and presents a visual perspective of how MGD and DED interact. It simplifies the existing information on how to differentiate between diagnosis of MGD and rosacea-associated MGD and summarises some of the emerging technologies for MGD diagnosis. Expert recommendations are given for the management of MGD and rosacea-associated MGD as well as highlighting the differences between them. By treating patients appropriately and early in the course of their disease, their outcomes are likely to be greatly improved.

Disclosures

Gerd Geerling has acted as a consultant and speaker for Allergan, Alcon, Bausch & Lomb, Chiesi, Oculus, Santen, Théa, TearLab and Tear Science. Christophe Baudouin has received research grants and consulting fees from Alcon, Allergan, Merck, Santen and Théa. Pasquale Aragona has acted as a consultant for Allergan, Alcon Italy, Bausch & Lomb, Santen, Medivis, Théa, Eupharmed and Farmigea and has received a research grant from SOOFT Italia and SIFI. Maurizio Rolando declares financial relationships with Allergan, Bausch & Lomb, Farmigea, Théa, Alcon, Eupharma, Santen/Novagali and Alfa Intes. Kostas G. Boboridis declares financial relationships with Allergan, Alcon, Théa and MSD. José M. Benítez-del-Castillo has acted as a consultant for Allergan, Bausch & Lomb, Théa, Alcon and Santen. Yonca A. Akova declares financial relationships with Allergan, Théa and Alcon. Jesús Merayo-Lloves has received research grants from Théa and has acted as a consultant for Allergan. Marc Labetoulle has acted as a consultant for Allergan, Alcon, Bausch & Lomb, Farmigea, MSD, Santen/Novagali and Théa. Martin Steinhoff declares financial relationships with Allergan and has received research funding from Galderma, Salix and L'Oréal. Elisabeth Messmer has acted as an advisor and presenter for Allergan, Alcon, Bausch & Lomb, Croma-Pharma, MSD, Oculus, Santen, Théa and Ursapharm.

Allergan provided funding for the meetings and for the development of this manuscript. The authors were involved with the entire process, from design to critical revision of the manuscript, and maintained complete control over the direction and content of the paper. Allergan did not have any influence on the manuscript content.

Osmoprotection in Dry Eye Disease – Expert Opinion (OCEAN) is a medical education program for general ophthalmologists that provides relevant, practical and up-to-date training on the management of dry eye disease. The content of this educational program is directed and created by the OCEAN faculty (the authors of this paper) with the support of Allergan.

This article was developed from a roundtable meeting held on 28 February–01 March 2014 by the OCEAN group in Valencia, Spain. The meeting was supported by an unrestricted grant from Allergan, who had no influence over the faculty discussions or content of this article. This article was further developed through discussion at subsequent meetings (16 January 2015, Paris, France, and 11–12 December 2015, Barcelona, Spain) and author

participation in teleconferences. All the authors contributed to the drafting of this manuscript, and it represents a consensus of their opinions gathered at the roundtable and subsequent meetings.

Acknowledgements

The authors thank Newton Healthcare Communications for writing and editing support, which was funded by Allergan, UK.

Appendix 1: Abbreviations

IPL	Intense pulsed light
OCEAN	Osmoprotection in Dry Eye Disease – Expert Opinion (a medical education programme)
OSD	Ocular surface disease
OSDI	Ocular Surface Disease Index
SIBO	Small intestine bacterial overgrowth
TBUT	Tear film break-up time
TFL	Tear film lipid layer

References

- [1] Qiao J, Yan X. Emerging treatment options for meibomian gland dysfunction. *Clin Ophthalmol* 2013;7:1797–803.
- [2] Bron AJ, Tiffany JM. The contribution of meibomian disease to dry eye. *Ocul Surf* 2004;2:149–65.
- [3] Tong L, Chaurasia SS, Mehta JS, Beueman RW. Screening for meibomian gland disease: its relation to dry eye subtypes and symptoms in a tertiary referral clinic in Singapore. *Invest Ophthalmol Vis Sci* 2010;51:3449–54.
- [4] Fahmy A, Hauswirth SG, Hardten DR. Treatments for meibomian gland dysfunction. *Ophthalmol Manag* 2014;(September):25–6.
- [5] Fenga C, Aragona P, Cacciola A, Spinella R, Di Nola C, Ferreri F, et al. Meibomian gland dysfunction and ocular discomfort in video display terminal workers. *Eye* 2008;22:91–5.
- [6] Nelson JD, Shimazaki J, Benitez-del-Castillo JM, Craig JP, McCulley JP, Den S, et al. The international workshop on meibomian gland dysfunction: report of the definition and classification subcommittee. *Invest Ophthalmol Vis Sci* 2011;52:1930–7.
- [7] Nichols KK, Foulks GN, Bron AJ, Glasgow BJ, Dogru M, Tsubota K, et al. The international workshop on meibomian gland dysfunction: executive summary. *Invest Ophthalmol Vis Sci* 2011;52:1922–9.
- [8] Maskin SL, Thomas P. The Causes. Reversing dry eye syndrome. Yale University Press; 2007. p. 44–71.
- [9] Tomlinson A, Bron AJ, Korb DR, Amano S, Paugh JR, Pearce EI, et al. The international workshop on meibomian gland dysfunction: report of the diagnosis subcommittee. *Invest Ophthalmol Vis Sci* 2011;52:2006–49.
- [10] Alvarenga LS, Mannis MJ. Ocular rosacea. *Ocul Surf* 2005;3:41–58.
- [11] Baudouin C, Aragona P, Messmer EM, Tomlinson A, Calonge M, Boboridis KG, et al. Role of hyperosmolarity in the pathogenesis and management of dry eye disease: proceedings of the OCEAN group meeting. *Ocul Surf* 2013;11:246–58.
- [12] Baudouin C. Revisiting meibomian gland dysfunction. *J Fr Ophthalmol* 2014;37:757–62.
- [13] Baudouin C, Messmer EM, Aragona P, Geerling G, Akova YA, Benítez-del-Castillo J, et al. Revisiting the vicious circle of dry eye disease: a focus on the pathophysiology of meibomian gland dysfunction. *Br J Ophthalmol* 2016;100:300–16.
- [14] McCulley JP, Shine WE. Meibomian gland function and the tear lipid layer. *Ocul Surf* 2003;1:97–106.
- [15] Ng EYK, Acharya UR, Rangayyan RM, Suri JS. In vivo confocal microscopy: imaging of the ocular surface. *Ophthalmological Imaging and Applications*. Taylor & Francis Group; 2014.
- [16] Knop E, Knop N, Millar T, Obata H, Sullivan DA. The international workshop on meibomian gland dysfunction: report of the subcommittee on anatomy, physiology, and pathophysiology of the meibomian gland. *Invest Ophthalmol Vis Sci* 2011;52:1938–78.
- [17] No authors listed. Methodologies to diagnose and monitor dry eye disease: report of the diagnostic methodology subcommittee of the international dry eye Workshop. *Ocul Surf* 2007;5:108–52.
- [18] Cogen AL, Nizet V, Gallo RL. Skin microbiota: a source of disease or defence? *Br J Dermatol* 2008;158:442–55.
- [19] Weinstock LB, Steinhoff M. Rosacea and small intestinal bacterial overgrowth: prevalence and response to rifaximin. *J Am Acad Dermatol* 2011;68:875–6.

- [20] Parodi A, Paolino S, Greco A, Drago F, Mansi C, Rebori A. Small intestinal bacterial overgrowth in rosacea: clinical effectiveness of its eradication. *Clin Gastro Hepat* 2008;6:759–64.
- [21] Hom MM, Martinson JR, Knapp LL, Paugh JR. Prevalence of Meibomian gland dysfunction. *Optom Vis Sci* 1990;67:710–2.
- [22] Matsumoto Y, Sato EA, Ibrahim OM, Dogru M, Tsubota K. The application of in vivo laser confocal microscopy to the diagnosis and evaluation of meibomian gland dysfunction. *Mol Vis* 2008;14:1263–71.
- [23] Schaumberg DA, Nichols JJ, Papas EB, Tong L, Uchino M, Nichols KK. The international workshop on meibomian gland dysfunction: report of the subcommittee on the epidemiology of, and associated risk factors for, MGD. *Invest Ophthalmol Vis Sci* 2011;52:1994–2005.
- [24] Viso E, Clemente MA, Rodriguez-Ares MT. Rosacea-associated meibomian gland dysfunction - an epidemiological perspective. *Eur Ophthalmol Rev* 2014;8:13–6.
- [25] Akpek EK, Merchant A, Pinar V, Foster CS. Ocular rosacea: patient characteristics and follow-up ophthalmology. *Ophthalmology* 1997;104:1863–7.
- [26] Viso E, Gude F, Rodriguez-Ares MT. The association of meibomian gland dysfunction and other common ocular diseases with dry eye: a population-based study in Spain. *Cornea* 2011;30:1–6.
- [27] Foulks GN, Nichols KK, Bron AJ, Holland EJ, McDonald MB, Nelson JD. Improving awareness, identification, and management of meibomian gland dysfunction. *Ophthalmology* 2012;119:S1–12.
- [28] Musumeci M, Aragona P, Bellini M, Maugeri F, Rania L, Bucolo C, et al. Acidic mammalian chitinase in dry eye conditions. *Cornea* 2009;28:667–72.
- [29] Aragona P, Aguenouz M, Rania L, Postorino E, Sommarino MS, Roszkowska AM, et al. Matrix metalloproteinase 9 and transglutaminase 2 expression at the ocular surface in patients with different forms of dry eye disease. *Ophthalmology* 2015;122:62–71.
- [30] Bron AJ, Yokoi N, Gafney E, Tiffany JM. Predicted phenotypes of dry eye: proposed consequences of its natural history. *Ocul Surf* 2009;7:78–92.
- [31] Randon M, Liang H, El Hamdaoui M, Tahiri R, Batellier L, Denoyer A, et al. In vivo confocal microscopy as a novel and reliable tool for the diagnosis of Demodex eyelid infestation. *Br J Ophthalmol* 2015;99:336–41.
- [32] Kuo TF, Tatsukawa H, Matsuura T, Nagatsuma K, Hirose S, Kojima S. Free fatty acids induce transglutaminase 2-dependent apoptosis in hepatocytes via ER stress-stimulated PERK pathways. *J Cell Physiol* 2012;227:1130–7.
- [33] Suzuki T, Teramukai S, Kinoshita S. Meibomian glands and ocular surface inflammation. *Ocul Surf* 2015;13:133–49.
- [34] Suzuki T. Meibomitis-related keratoconjunctivitis: implications and clinical significance of meibomian gland inflammation. *Cornea* 2012;31(Suppl 1):S41–4.
- [35] Goto E, Tseng SC. Differentiation of lipid tear deficiency dry eye by kinetic analysis of tear interference images. *Arch Ophthalmol* 2003;121:173–80.
- [36] Murube J, Nemeth J, Hoh H, Kaynak-Hekimhan P, Horwath-Winter J, Agarwal A, et al. The triple classification of dry eye for practical clinical use. *Eur J Ophthalmol* 2005;15:660–7.
- [37] Heiligenhaus A, Koch JM, Kruse FE, Schwarz C, Waubke TN. Diagnosis and differentiation of dry eye disorders. *Ophthalmologie* 1995;92:6–11.
- [38] Lemp MA, Crews LA, Bron AJ, Foulks GN, Sullivan BD. Distribution of aqueous-deficient and evaporative dry eye in a clinic-based patient cohort: a retrospective study. *Cornea* 2012;31:472–8.
- [39] Powell DR, Nichols JJ, Nichols KK. Inter-examiner reliability in meibomian gland dysfunction assessment. *Invest Ophthalmol Vis Sci* 2012;53:3120–5.
- [40] Wilkin J, Dahl M, Detmar M, Drake L, Feinstein A, Odom R, et al. Standard classification of rosacea: report of the national rosacea society expert committee on the classification and staging of rosacea. *J Am Acad Dermatol* 2002;46:584–7.
- [41] Finis D, Pischel N, König C, Hayajneh J, Borrelli M, Schrader S, et al. Comparison of the OSDI and SPEED questionnaires for the evaluation of dry eye disease in clinical routine. *Ophthalmologie* 2014;111:1050–6.
- [42] Arita R, Itoh K, Maeda S, Maeda K, Tomidokoro A, Amano S. Efficacy of diagnostic criteria for the differential diagnosis between obstructive meibomian gland dysfunction and aqueous deficiency dry eye. *Jpn J Ophthalmol* 2010;54:387–91.
- [43] Arita R, Itoh K, Maeda S, Maeda K, Furuta A, Fukuoka S, et al. Proposed diagnostic criteria for obstructive meibomian gland dysfunction. *Ophthalmology* 2009;116:2058–63.
- [44] Foulks GN, Bron AJ. Meibomian gland dysfunction: a clinical scheme for description, diagnosis, classification, and grading. *Ocul Surf* 2003;1:107–26.
- [45] Blackie CA, Korb DR, Knop E, Bedi R, Knop N, Holland EJ. Nonobvious obstructive meibomian gland dysfunction. *Cornea* 2010;29:1333–45.
- [46] (No authors listed). The definition and classification of dry eye disease: report of the definition and classification subcommittee of the international dry eye Workshop. *Ocul Surf* 2007;2007(5):75–92.
- [47] Zengin N, Tol H, Gündüz K, Okudan S, Balevi S, Endoğlu H. Meibomian gland dysfunction and tear film abnormalities in rosacea. *Cornea* 1995;2:144–6.
- [48] Kocak-Altıntaş AG, Kocak-Midillioglu I, Gul U, Bilezikci B, Isikşacan O, Duman S. Impression cytology and ocular characteristics in ocular rosacea. *Eur J Ophthalmol* 2003;13:351–9.
- [49] Pisella PJ, Brignole F, Debbasch C, Lozato PA, Creuzot-Garcher C, Bara J, et al. Flow cytometric analysis of conjunctival epithelium in ocular rosacea and keratoconjunctivitis sicca. *Ophthalmology* 2000;107:1841–9.
- [50] Karaman ES, Eliaciik M, Kocabora MS, Balevi A, Demirci G, Ozsutcu M, et al. Tear osmolarity and tear film parameters in patients with ocular rosacea. *Eye Contact Lens* 2016;42(6):347–9.
- [51] Palamar M, Degirmenci C, Ertam I, Yağcı A. Evaluation of dry eye and meibomian gland dysfunction with meibography in patients with rosacea. *Cornea* 2015;34:497–9.
- [52] Zeev MS, Miller DD, Latkany R. Diagnosis of dry eye disease and emerging technologies. *Clin Ophthalmol* 2014;8:581–90.
- [53] Mitra M, Menon GJ, Casini A, Hamada S, Adams D, Ricketts C, et al. Tear film lipid layer thickness and ocular comfort after meibomian therapy via latent heat with a novel device in normal subjects. *Eye* 2005;19:657–60.
- [54] Ophthalmology Management. Tearscope-plus. Available at: <http://www.ophtalmologymanagement.com/articleviewer.aspx?articleID=5727>. Accessed October 2014.
- [55] Keeler ophthalmic instruments. Keeler history. Available at: http://www.keeler.co.uk/keeler_history.htm. Accessed October 2014.
- [56] García-Resúa C, Giraldez Fernandez MJ, Gonzalez Penedo MF, Calvo D, Penas M, Yebra-Piemenel E. New software application for clarifying tear film lipid layer patterns. *Cornea* 2013;32:538–46.
- [57] García-Resúa C, Pena-Verdeal H, Minones M, Giraldez MJ, Yebra-Pimentel E. Interobserver and intraobserver repeatability of lipid layer pattern evaluation by two experienced observers. *Contact Lens Anterior Eye* 2014;37:431–7.
- [58] Hosaka E, Kawamorita T, Ogasawara Y, Nakayama N, Uozato H, Shimizu K, et al. Interferometry in the evaluation of precorneal tear film thickness in dry eye. *Am J Ophthalmol* 2011;151:18–23.
- [59] Finis D, Pischel N, Schrader S, Geerling G. Evaluation of lipid layer thickness measurement of the tear film as a diagnostic tool for Meibomian gland dysfunction. *Cornea* 2013;32:1549–53.
- [60] Rolando M, Valente C, Barabino S. New test to quantify lipid layer behaviour in healthy subjects and patients with keratoconjunctivitis sicca. *Cornea* 2008;27:866–70.
- [61] Yokoi N, Komuro A, Maruyama K, Kinoshita S. New instruments for dry eye diagnosis. *Semin Ophthalmol* 2005;20:63–70.
- [62] Eom Y, Lee JS, Kang SY, Kim HM, Song JS. Correlation between quantitative measurements of tear film lipid layer thickness and meibomian gland loss in patients with obstructive meibomian gland dysfunction and normal controls. *Am J Ophthalmol* 2013;155:1104–10.
- [63] Wise RJ, Sobel RK, Allen RC. Meibography: a review of techniques and technologies. *Saudi J Ophthalmol* 2012;26:349–56.
- [64] Arita R. Validity of noninvasive meibography systems: noncontact meibography equipped with a slit-lamp and a mobile pen-shaped meibograph. *Cornea* 2013;32(Suppl 1):S65–70.
- [65] Arita R, Itoh K, Inoue K, Amano S. Noncontact infrared meibography to document age-related changes of the meibomian glands in a normal population. *Ophthalmology* 2008;115:911–5.
- [66] Yokoi N, Komuro A, Yamada H, Maruyama K, Kinoshita S. A newly developed video. A newly developed video-meibography system featuring a newly designed probe. *Jpn J Ophthalmol* 2007;51:53–6.
- [67] Arita R, Itoh K, Maeda S, Maeda K, Amano S. A newly developed noninvasive and mobile pen-shaped meibography system. *Cornea* 2013;32:242–7.
- [68] Nichols JJ, Berntsen DA, Mitchell GL, Nichols KK. An assessment of grading scales for meibography images. *Cornea* 2005;24:382–8.
- [69] Pult H, Riede-Pult BH. Non-contact meibography: keep it simple but effective. *Cont Lens Anterior Eye* 2012;35:77–80.
- [70] Finis D, Ackermann P, Pischel N, König C, Hayajneh J, Borrelli M, et al. Evaluation of Meibomian gland dysfunction and local distribution of meibomian gland atrophy by non-contact infrared meibography. *Curr Eye Res* 2015;40:982–9.
- [71] Arita R, Suehiro J, Haraguchi T, König C, Hayajneh J, Borrelli M, et al. Objective image analysis of the meibomian gland area. *Br J Ophthalmol* 2013;98:746–55.
- [72] Srinivasan S, Menzies K, Sorbara L, Jones L. Infrared imaging of meibomian gland structure using a novel keratograph. *Optom Vis Sci* 2012;89:788–94.
- [73] Best N, Drury L, Wolffsohn JS. Clinical evaluation of the oculus keratograph. *Cont Lens Anterior Eye* 2012;35:171–4.
- [74] Messmer EM, Torres Suárez E, Mackert MI, Zapp DM, Kampik A. In-vivo confocal. In-vivo confocal microscopy in blepharitis. *Klin Monatsbl Augenheilkd* 2005;222:894–900.
- [75] Villani E, Beretta S, De CM, Galimberti D, Viola F, Ratiglia R. In vivo confocal microscopy of meibomian glands in Sjogren's syndrome. *Invest Ophthalmol Vis Sci* 2011;52:933–9.
- [76] Ibrahim OM, Matsumoto Y, Dogru M, Adan ES, Wakamatsu TH, Goto T, et al. The efficacy, sensitivity, and specificity of in vivo laser confocal microscopy in the diagnosis of meibomian gland dysfunction. *Ophthalmology* 2010;117:665–72.
- [77] Holmes AD. Potential role of microorganisms in the pathogenesis of rosacea. *J Am Acad Dermatol* 2013;69:1025–32.
- [78] Niyadurupola N, Astbury N. Endophthalmitis: controlling infection before and after cataract surgery. *Community Eye Health J* 2008;21:9–10.
- [79] Krader CG, Akpek EK. Managing MGD still a challenge. Available at: <http://ophthalmologytimes.modernmedicine.com/ophthalmologytimes/content/tags/essen-k-akpek/managing-mgd-still-challenge>. Accessed 29 September 2015.
- [80] Geerling G, Tauber J, Baudouin C, Goto E, Matsumoto Y, O'Brien T, et al. The international workshop on meibomian gland dysfunction: report of the subcommittee on management and treatment of meibomian gland

- dysfunction. *Invest Ophthalmol Vis Sci* 2011;52:2050–64.
- [81] Finis D, Hayajneh J, Konig C, Borrelli M, Schrader S, Geerling G. Evaluation of an automated thermodynamic treatment (LipiFlow) system for meibomian gland dysfunction: a prospective, randomized, observer-masked trial. *Ocul Surf* 2014;12:146–54.
- [82] Gao YY, Di Pascuale MA, Li W, Baradaran-Rafii A, Elizondo A, Kuo CL, et al. In vitro and in vivo killing of ocular Demodex by tea tree oil. *Br J Ophthalmol* 2005;89:1468–73.
- [83] Shine WE, McCulley JP. Polar lipids in human meibomian gland secretions. *Curr Eye Res* 2003;26:89–94.
- [84] Korb DR, Blackie CA. Meibomian gland therapeutic expression: quantifying the applied pressure and the limitation of resulting pain. *Eye Contact Lens* 2011;37:298–301.
- [85] Bilkhu PS, Naroo SA, Wolffsohn JS. Randomised masked clinical trial of the MGDx eyeab for the treatment of meibomian gland dysfunction-related evaporative dry eye. *Br J Ophthalmol* 2014;98:1707–11.
- [86] Benitez Del Castillo JM, Kaercher T, Mansour K, Wylegala E, Dua H. Evaluation of the efficacy, safety, and acceptability of an eyelid warming device for the treatment of meibomian gland dysfunction. *Clin Ophthalmol* 2014;8:2019–27.
- [87] Arita R, Morishige N, Shirakawa R, Sato Y, Amano S. Effects of eyelid warming devices on tear film parameters in normal subjects and patients with meibomian gland dysfunction. *Ocul Surf* 2015;13:321–30.
- [88] MiBo Medical Group. MiBo ThermoFlo clinical research. Available at: <http://mibomedicalgroup.com/clinical-research/>. Accessed 18 June 2016.
- [89] Baumann A, Cochener B. Meibomian gland dysfunction: a comparative study of modern treatments. *J Fr Ophtalmol* 2014;37:303–12.
- [90] Finis D, Konig C, Hayajneh J, Borrelli M, Schrader S, Geerling G. Six month effects of a thermodynamic treatment. Six month effects of a thermodynamic treatment for MGD and implications of meibomian gland atrophy. *Cornea* 2014;33:1265–70.
- [91] Korb DR, Blackie CA. Debridement-scaling: a new procedure that increases Meibomian gland function and reduces dry eye symptoms. *Cornea* 2013;32:1554–7.
- [92] Scope ophthalmics. BlepEx blepharitis treatment. 2015.
- [93] Toyos R, McGill W, Briscoe D. Intense pulsed light treatment for dry eye disease due to meibomian gland dysfunction; a 3-year retrospective study. *Photomed Laser Surg* 2015;33:41–6.
- [94] Lee SY, Tong L. Lipid-containing lubricants for dry eye: a systematic review. *Optom Vis Sci* 2012;89:1654–61.
- [95] Epharma.it. Cationorm multi ophthalmic emulsion 10ml helps to moisten, lubricate and protect the eye surface. Available at: <http://www.efarma.it/en/cationorm-multi-akiu-lasai-emulsija-10ml>. Accessed 1 July 2016.
- [96] Kaercher T, Thelen U, Brief G, Morgan-Warren RJ, Leaback R. A prospective, multicentre, non-interventional study of Optive Plus® in the treatment of patients with dry eye: the prolipid study. *Clin Ophthalmol* 2014;8:1147–55.
- [97] Bausch+Lomb Bausch+Lomb: Soothe XP-Xtra protection Emollient (lubricant) eye drops. 2016.
- [98] Benelli U. Systane lubricant eye drops in the management of ocular dryness. *Clin Ophthalmol* 2011;5:783–90.
- [99] Dausch D, Lee S, Dausch S, Kim JC, Schwert G, Michelson W. Comparative study of treatment of the dry eye syndrome due to disturbances of the tear film lipid layer with lipid-containing tear substitutes. *Klin Monbl Augenheilkd* 2006;223:974–83.
- [100] Craig JP, Purslow C, Murphy PJ, Wolffson JF. Effect of a liposomal spray on the pre-ocular tear film. *Cont Lens Anterior Eye* 2010;33:83–7.
- [101] Steven P, Scherer D, Krosser S, Beckert M, Cursiefen C, Kaercher T. Semi-fluorinated alkane eye drops for treatment of dry eye disease—a prospective, multicenter noninterventional study. *J Ocul Pharmacol Ther* 2015;31:498–503.
- [102] Foulks GN, Borchman D, Yappert M, Kim SH, McKay JW. Topical azithromycin therapy for meibomian gland dysfunction: clinical response and lipid alterations. *Cornea* 2010;29:781–8.
- [103] Aghai ZH, Kode A, Saslow JG, Nakhla T, Farhath S, Stahl GE, et al. Azithromycin suppresses activation of nuclear factor-kappa B and synthesis of pro-inflammatory cytokines in tracheal aspirate cells from premature infants. *Pediatr Res* 2007;62:483–8.
- [104] Li DQ, Zhou N, Zhang L, Ma P, Pflugfelder SC. Suppressive effects of azithromycin on zymosan-induced production of proinflammatory mediators by human corneal epithelial cells. *Invest Ophthalmol Vis Sci* 2010;51:5623–9.
- [105] Zhang L, Su Z, Zhang Z, Lin J, Li DQ, Pflugfelder SC. Effects of Azithromycin on gene expression profiles of proinflammatory and anti-inflammatory mediators in the eyelid margin and conjunctiva of patients with meibomian gland disease. *JAMA Ophthalmol* 2015;133:1117–23.
- [106] Foulks GN, Borchman D, Yappert M, Kakar S. Topical azithromycin and oral doxycycline therapy of meibomian gland dysfunction: a comparative clinical and spectroscopic pilot study. *Cornea* 2013;32:44–53.
- [107] Perry HD, Solomon R, Donnenfeld ED, Perry AR, Wittmann JR, Greenman HE, et al. Evaluation of topical cyclosporine for the treatment of dry eye disease. *Arch Ophthalmol* 2008;126:1046–50.
- [108] Perry HD, hi-Carnevale S, Donnenfeld ED, Solomon R, Biser SA, Bloom AH. Efficacy of commercially available topical cyclosporine A 0.05% in the treatment of meibomian gland dysfunction. *Cornea* 2006;25:171–5.
- [109] Prabhawast P, Tesavibul N, Mahawong W. A randomized double-masked study of 0.05% cyclosporine ophthalmic emulsion in the treatment of meibomian gland dysfunction. *Cornea* 2012;12:1386–93.
- [110] Rubin M, Rao SN. Efficacy of topical cyclosporin 0.05% in the treatment of posterior blepharitis. *J Ocul Pharmacol Ther* 2006;22:47–53.
- [111] Macsai MS. The role of omega-3 dietary supplementation in blepharitis and meibomian gland dysfunction (an AOS thesis). *Trans Am Ophthalmol Soc* 2008;106:336–56.
- [112] Brignole-Baudouin F, Baudouin C, Aragona P, Rolando M, Labetoulle M, Pisella PJ, et al. A multicentre, double-masked, randomized, controlled trial assessing the effect of oral supplementation of omega-3 and omega-6 fatty acids on a conjunctival inflammatory marker in dry eye patients. *Acta Ophthalmol* 2011;89:e591–7.
- [113] Barabino S, Rolando M, Camicione P, Ravera G, Zanardi S, Giuffrida S, et al. Systemic linoleic and gamma-linolenic acid therapy in dry eye syndrome with an inflammatory component. *Cornea* 2003;22:97–101.
- [114] Aragona P, Bucolo C, Spinella R, Giuffrida S, Ferreri G. Systemic omega-6 essential fatty acid treatment and pge1 tear content in Sjogren's syndrome patients. *Invest Ophthalmol Vis Sci* 2005;46:4474–9.
- [115] Macri A, Giuffrida S, Amico V, Lester M, Traverso CE. Effect of linoleic acid and gamma-linolenic acid on tear production, tear clearance and on the ocular surface after photorefractive keratectomy. *Graefes Arch Clin Exp Ophthalmol* 2003;241:561–6.
- [116] Avunduk AM, Avunduk MC, Varnell ED, Kaufman HE. The comparison of efficacies of topical corticosteroids and nonsteroidal anti-inflammatory drops on dry eye patients: a clinical and immunocytochemical study. *Am J Ophthalmol* 2003;136:593–602.
- [117] Carnahan MC, Goldstein DA. Ocular complications of topical, peri-ocular, and systemic corticosteroids. *Curr Opin Ophthalmol* 2000;11:478–83.
- [118] Chen AY, Zirwas MJ. Steroid-induced rosacea-like dermatitis: case report and review of the literature. *Cutis* 2009;83:198–204.
- [119] Maskin SL. Intraductal meibomian gland probing relieves symptoms of obstructive meibomian gland dysfunction. *Cornea* 2010;29:1145–52.
- [120] Intraductal Meibomian Gland Probing Trial (MGP). Available at: <https://clinicaltrials.gov/ct2/show/NCT02256969>.
- [121] Vieira AC, Mannis MJ. Ocular rosacea: common and commonly missed. *J Am Acad Dermatol* 2013;69:S36–41.
- [122] Sobolewska B, Doycheva D, Deuter C, Pfeffer I, Schaller M, Zierhut M. Treatment of ocular rosacea with once-daily low-dose doxycycline. *Cornea* 2014;33:257–60.
- [123] Quarterman MJ, Johnson DW, Abele DC, Leshner Jr JL, Hull DS, Davis LS. Ocular rosacea. Signs, symptoms, and tear studies before and after treatment with doxycycline. *Arch Dermatol* 1997;133:49–54.
- [124] FGK Representative Service GmbH. Oracea summary of product characteristics. Available at: http://www.ema.europa.eu/docs/en_GB/document_library/Referrals_document/Oracea_29/WC500008121.pdf. Accessed 4 February 2015.
- [125] Steinhoff M, Schaubert J, Leyden JJ. New insights into rosacea pathophysiology: a review of recent findings. *J Am Acad Dermatol* 2013;69:S15–26.
- [126] Ngo W, Srinivasan S, Jones L. Historical overview of imaging the meibomian glands. *J Optom* 2013;6:1–8.
- [127] Caffery BE, Richter D, Simpson T, Fonn D, Doughty M, Gordon K. CANDEES. The canadian dry eye epidemiology CANDEES. The canadian dry eye epidemiology study. *Adv Exp Med Biol* 1998;438:805–6.
- [128] Begley CG, Caffery B, Chalmers RL, Mitchell GL. Dry Eye Investigation (DREI) Study Group. Use of the dry eye questionnaire to measure symptoms of ocular irritation in patients with aqueous tear deficient dry eye. *Cornea* 2002;21:664–70.
- [129] Rajagopalan K, Abetz L, Mertzanis P, Espindle D, Begley C, Chalmers R, et al. Comparing the discriminative validity of two generic and one disease-specific health-related quality of life measures in a sample of patients with dry eye. *Value Health* 2005;8:168–74.
- [130] Abetz L, Rajagopalan K, Mertzanis P, Begley C, Barnes R, Chalmers R, et al. Development and validation of the impact of dry eye on everyday life (IDEEL) questionnaire, a patient-reported outcomes (PRO) measure for the assessment of the burden of dry eye on patients. *Health Qual Life Outcomes* 2011;9:111.
- [131] Vitali C, Bombardieri S, Jonsson R, Moutsopoulos HM, Alexander EL, Carson SE, et al. Classification criteria for Sjogren's syndrome: a revised version of the European criteria proposed by the American-European Consensus Group. *Ann Rheum Dis* 2002;61:554–8.
- [132] Shiboski SC, Shiboski CH, Criswell L, Baer A, Challacombe S, Lanfranchi H, et al. American College of Rheumatology classification criteria for Sjogren's syndrome: a data-driven, expert consensus approach in the Sjogren's International Collaborative Clinical Alliance cohort. *Arthritis Care Res Hob* 2012;64:475–87.
- [133] McMonnies CW, Ho A. Patient history in screening for dry eye conditions. *J Am Optom Assoc* 1987;58:296–301.
- [134] McMonnies CW, Ho A. Responses to a dry eye questionnaire from a normal population. *J Am Optom Assoc* 1987;58:588–91.
- [135] Baudouin C, Creuzot-Garcher C, Hoang-Xuan T, Rigeade MC, Brouquet Y, Bassols A, et al. Creating a specific diagnostic and quality-of-life questionnaire for patients with ocular surface disease. *J Fr Ophtalmol* 2003;26:119–30.
- [136] Baudouin C, Creuzot-Garcher C, Hoang-Xuan T, Rigeade MC, Brouquet Y, Bassols A, et al. Severe impairment of health-related quality of life in patients

- suffering from ocular surface diseases. *J Fr Ophtalmol* 2008;31:369–78.
- [137] Dry Eye Zone. Ocular surface disease Index (OSDI). Available at: <http://www.dryeyezone.com/documents/osdi.pdf>. Accessed 16 February 2015.
- [138] Schiffman RM, Christianson MD, Jacobsen G, Hirsch JD, Reis BL. Reliability and validity of the ocular surface disease index. *Arch Ophthalmol* 2000;118:615–21.
- [139] Schein OD, Tielsch JM, Munoz B, Bandeen-Roche S, West S. Relation between signs. Relation between signs and symptoms of dry eye in the elderly. A population-based perspective. *Ophthalmology* 1997;104:1395–401.
- [140] Korb DR, Scaffidi RC, Greiner JV, Kenyon KR, Herman JP, Blackie CA, et al. The effect of two novel lubricant eye drops on tear film lipid layer thickness in subjects with dry eye symptoms. *Optom Vis Sci* 2005;82:594–601.
- [141] Schaumberg DA, Sullivan DA, Buring JE, Dana MR. Prevalence of dry eye syndrome among US women. *Am J Ophthalmol* 2003;136:318–26.
- [142] Miljanovic B, Dana R, Sullivan DA, Schaumberg DA. Impact of dry eye syndrome on vision-related quality of life. *Am J Ophthalmol* 2007;143:409–15.